ultrasound VILLAGE

LUNG ULTRASOUND

This is a focussed lung ultrasound.
Sensitivity and specificity vary by condition, sonographer experience and patient body habitus.
Correlate with clinical findings and consider underlying lung disease in the interpretation of images.
Correlate with other imaging where possible.

Patient details

History

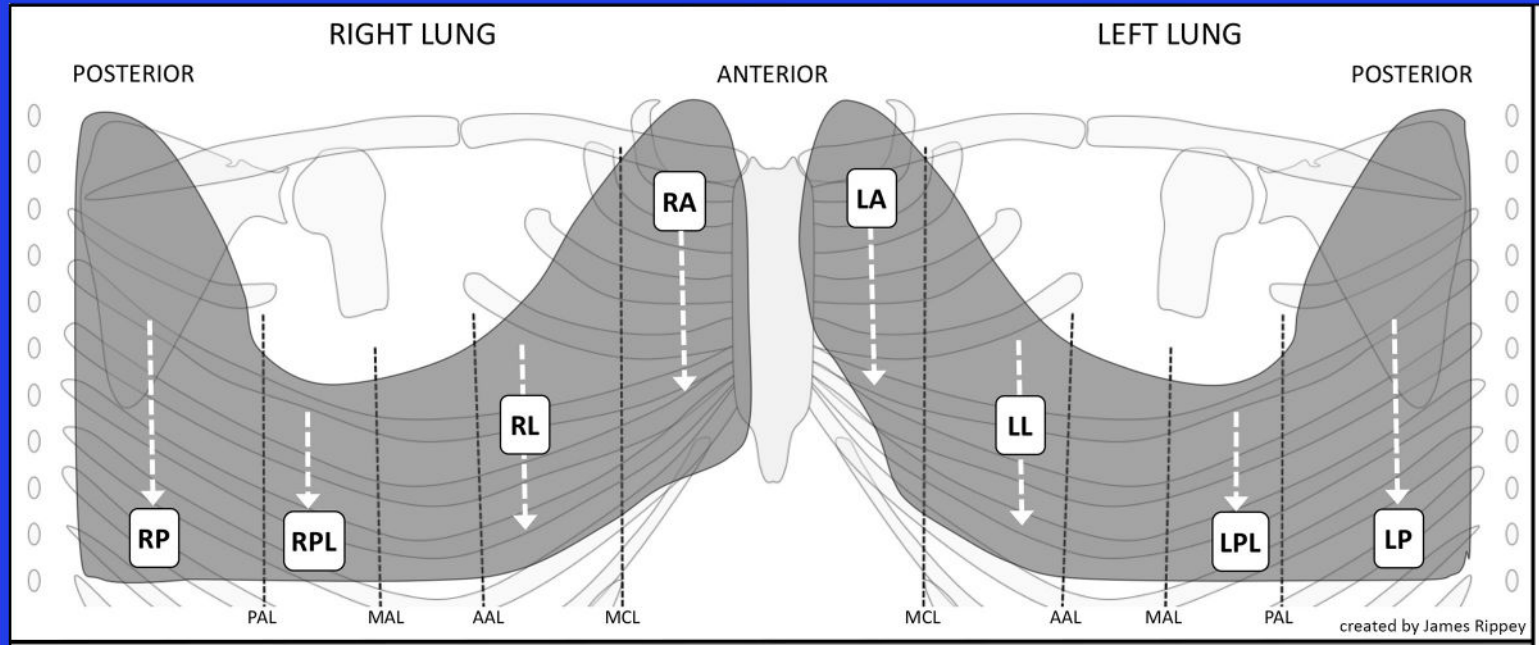

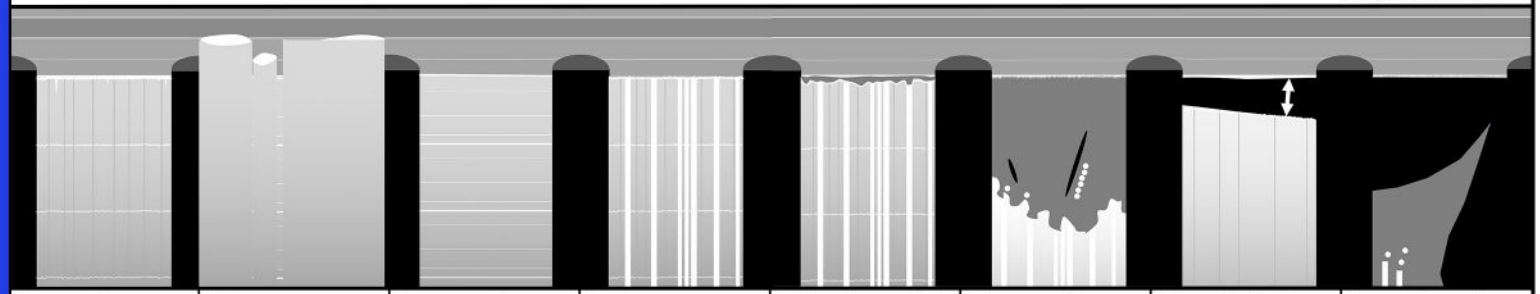

Normal lung	Subcutaneous emphysema	Pneumothorax	Pulmonary oedema	Other interstitial alveolar synd	Pneumonia	Pleural effusion	Large pleural effusion
Lung sliding present Lung pulse present Movement at pleural surface and below Few but definite short path reverb artefacts (comet tails and B-lines) Weak long path reverb artefacts (A-lines)	Air in soft tissues May obscure ribs and lung Free air does not slide but probe pressure can displace air laterally Pattern depends on location of air	Loss of lung sliding No movement below pleural line No comet tails Dominant A-lines Lung point Consider other causes of reduced lung sliding and reduced markings	> 2 B-lines per rib space; diffuse B-lines start at pleural line and extend to deepest part of image May have pleural effusions Consider echo	Multiple B-lines often patchy Irregular pleural line with "subpleural consolidation" Pneumonitis, ARDS, lung fibrosis, lymphangitis, contusion	Early - B-lines, then Hepatisation Irregular aerated lung border - shred sign Air bronchograms B-lines deep to consolidation May be assoc pleural effusion	Quadratic sign Sinusoidal sign of lung movement with respiration Look for echoes, depth, extent, loculations, nodules Beware hypoechoic solid pleural tumour	Compressed mobile underlying lung with scalloped border **Other** Lung and pleural tumours, pulmonary infarction

Clinical Findings

P BP Temp RR Sats

Comment: _____

Ultrasound Findings

Right Anterior _____

Right Lateral _____

Right Postero Lateral _____

Right Posterior _____

Left Anterior _____

Left Lateral _____

Left Postero Lateral _____

Left Posterior _____

Other (e.g. echo, IVC, deep veins) _____

Comments & Conclusion

_____

Lung ultrasound findings should not be used in isolation; correlate with clinical findings and other imaging

Clinician: **Signature:** **Date:**

LUNG ULTRASOUND REPORT