

ID NUMBER:

--	--	--	--	--

**University Hospital, Geelong
Emergency Medicine
Trial Fellowship Exam
Short Answer Questions (SAQ)
Week 3**

DIRECTIONS TO CANDIDATE

1. Answer each question in the space provided in this question paper.
2. Do not write your name on this question paper.
3. Enter your examination number in the space below.
4. Cross out any errors completely.
5. Do not begin the exam until instructed to do so.
6. Do not take examination paper or materials from this room.
7. The booklet binder may be removed during the exam.

**QUESTION & ANSWER
BOOKLET**

Question 1 (19 marks) 9 minutes

You are assigned to be the retrieval doctor by fixed wing aircraft, for a 68 year old male who has been involved in a rollover car collision. The patient is located in regional centre that does not have CT facilities. After your clinical review, he appears to have isolated head and chest injuries.

A CXR is taken soon after the patient's arrival- see props booklet- page 1.

a. State three (3) abnormal findings shown in this CXR. (3 marks)

1. _____
2. _____
3. _____

You decide to place a central venous line prior to transfer.

b. List your preferred site for placement of this line in this patient? (1 mark)

c. State three (3) justifications for your choice of site. (3 marks)

1. _____
2. _____
3. _____

Question 1 (continued)

- d. List six (6) specific medical problems that you would anticipate during the transport of this patient. For each problem state one (1) measure that you would take to minimise the likelihood of each problem. (12 marks)

	Specific medical problem (6 marks)	Measure you would take to minimise the problem (6 marks)
1		
2		
3		
4		
5		
6		

Question 2 (12 marks) 6 minutes

A mother presents with her very distressed 18 month old child. The mother is concerned that the child may have eaten powder detergent from the dishwasher, 30 minutes ago.

a. List three (3) features of toxicity of this ingestion. (3 marks)

1. _____

2. _____

3. _____

b. What is the specific decontamination that is required if particular matter is found in the mouth? (1 mark)

c. What is the treatment of choice if toxicity is suspected. (1 mark)

Question 2 (continued)

After complete assessment, the child appears to have isolated ocular exposure to the washing powder.

d. Other than referral to Ophthalmology, list (5) steps in the management of this exposure. (5 marks)

1. _____

2. _____

3. _____

4. _____

5. _____

e. List three (3) indications for urgent Ophthalmological referral. (3 marks)

1. _____

2. _____

3. _____

Question 3 (14 marks) 6 minutes

An 18 year old year old female presents with a 2 week history of malaise, cough and shortness of breath. A CXR shows a large right pleural effusion.

A pleural aspirate is taken- see the props booklet- page 2

- a. List four (4) likely differential diagnoses for this patient. For each diagnosis, state how the diagnosis would be confirmed. (8 marks)

	Diagnosis (4 marks)	How is the diagnosis made? (4 marks)
1		
2		
3		
4		

Question 3 (continued)

b. List four (4) indications for therapeutic needle thoracocentesis in this patient. (4 marks)

1. _____

2. _____

3. _____

4. _____

Question 4 (15 marks) 6 minutes

A 23 year old man presents with a complaint of palpitations and dizziness.
His vital signs on presentation include:

BP	70/50 mmHg
RR	16 /min
Temp	37 °C
GCS	15

An ECG is taken on presentation- see props booklet page 3.

a. State seven (7) abnormal findings for this ECG. (7 marks)

1. _____
2. _____
3. _____
4. _____
5. _____
6. _____
7. _____

Question 4 (continued)

b. List three (3) possible causes for this condition in this patient. (3 marks)

1. _____

2. _____

3. _____

c. What is your first line treatment for this patient. (1 mark)

d. State four (4) possible additional treatments for this patient, following your first line treatment. (4 marks)

1. _____

2. _____

3. _____

4. _____

Question 5 (12 marks) 6 minutes

A 2 ½ year old female presented with a history of injuring her feet on hot bitumen. She is very distressed with pain.

A photograph of the child is taken after her feet have been cleaned- see props booklet page 4.

a. State four (4) steps in your management of her pain. (4 marks)

1. _____

2. _____

3. _____

4. _____

Question 5 (continued)

- b. Other than analgesia, list four (4) key issues in the management of this child. Provide one justification for the importance of each issue. (8 marks)

	Important management issue (4 marks)	Justification (4 marks)
1		
2		
3		
4		

Question 6 (15 marks) 6 minutes

- a. List five (5) anatomical structures that may be involved in Herpes Zoster Ophthalmicus. (5 marks)

1. _____
2. _____
3. _____
4. _____
5. _____

Question 6 (continued)

A 36 year old male presents to ED with sudden loss of vision in his left eye.

- b. Other than Herpes Zoster Ophthalmicus, state five (5) likely diagnoses. For each diagnosis, list one (1) characteristic examination findings of each condition. (10 marks)

	Diagnosis (5 marks)	Characteristic examination finding (5 marks)
1		
2		
3		
4		
5		

Question 7 (12 marks) 6 minutes

A 45 year old male presents to ED with vertigo and ataxia.

A CT scan is taken- refer to the props booklet- page 5.

a. State four (4) abnormal findings shown in this image. (4 marks)

1. _____

2. _____

3. _____

4. _____

Question 7 (continued)

- b. List four (4) key investigations that you would perform in this patient. Provide one (1) justification for each choice. (8 marks)

	Investigations (4 marks)	Justification (4 marks)
1		
2		
3		
4		

Question 8 (12 marks) 6 minutes

A 30 year old female who is 36 weeks pregnant presents to the ED with an ongoing tonic clonic seizure. She has received no prehospital care. She is triaged to a resuscitation cubicle with standard non-invasive monitoring. She has IV access.

Her observations include:

BP	190/120	mmHg
PR	120	/min
RR	18	/min
Temp	37	°C

- a. List four (4) key steps to the management of this patient over the next 1 hour. Provide one (1) detail for each step. (8 marks)

	Management step (4 marks)	Detail (4 marks)
1		
2		
3		
4		

Question 8 (continued)

You are unable to contact the Obstetric registrar via the on call mobile phone number.

b. State four (4) steps to rectify this problem. (4 marks)

1. _____

2. _____

3. _____

4. _____

Question 9 (18 marks) 9 minutes

Your director is keen to commence a chest pain unit in your department.

a. State four (4) advantages of a chest pain unit. (4 marks)

1. _____

2. _____

3. _____

4. _____

b. State four (4) disadvantages of a chest pain unit. (4 marks)

1. _____

2. _____

3. _____

4. _____

Question 9 (continued)

Your director suggests using the TIMI risk score as a discharge decision tool.

c. List the seven (7) components of the TIMI risk score. (7 marks)

1. _____
2. _____
3. _____
4. _____
5. _____
6. _____
7. _____

Question 9 (continued)

d. State three (3) limitations of applying the TIMI score to ED patients. (3 marks)

1. _____

2. _____

3. _____

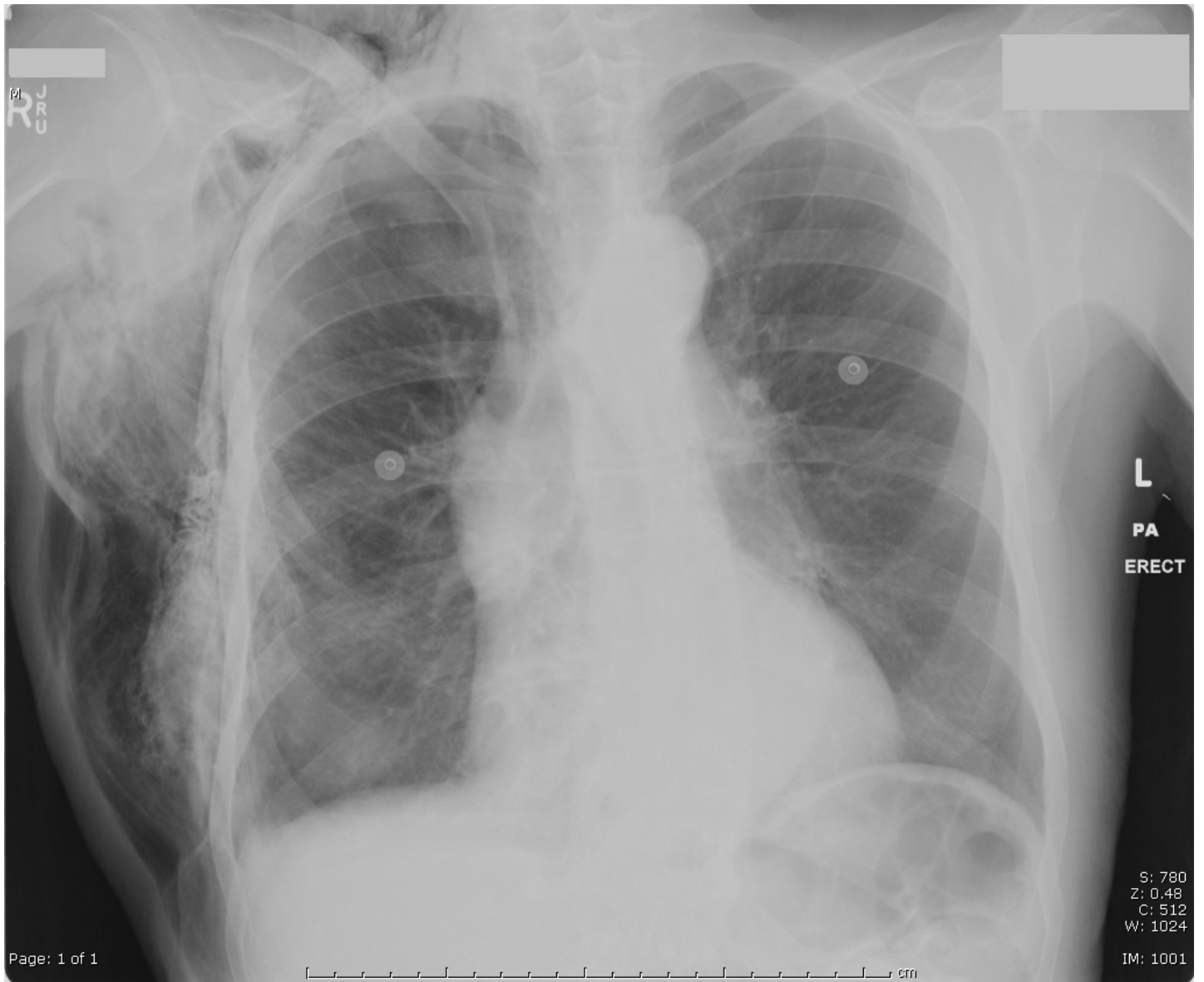ID NUMBER:

<input type="text"/>	<input type="text"/>	<input type="text"/>	<input type="text"/>	<input type="text"/>
----------------------	----------------------	----------------------	----------------------	----------------------

**University Hospital, Geelong
Emergency Medicine
Trial Fellowship Exam
Short Answer Questions (SAQ)
Week 3**

PROP BOOKLET

Question 1



Question 2

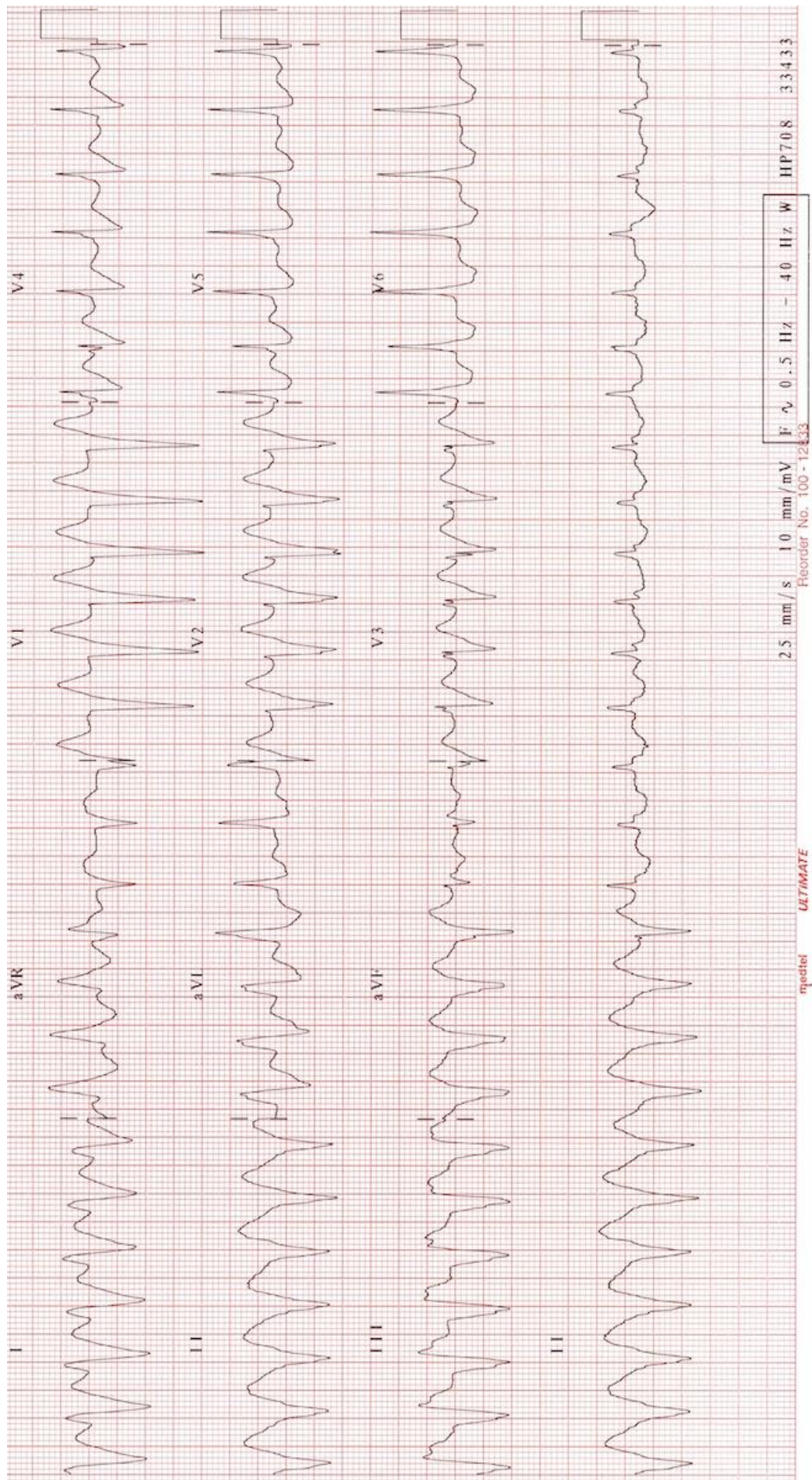
Site: Pleural

Appearance: Hazy

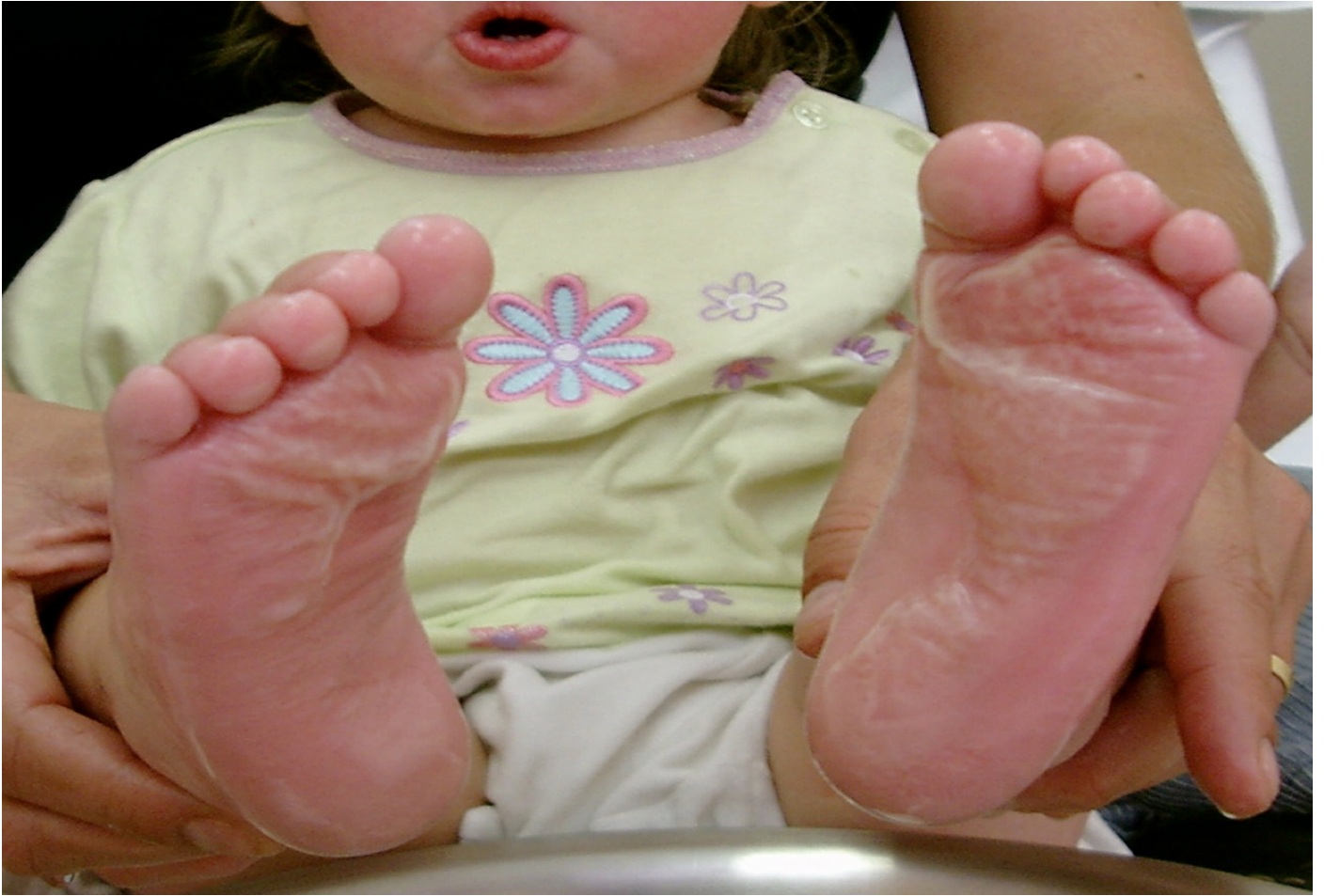Supernatant: Clear yellow

			Reference range
<u>CELL COUNT:</u>	White cells	800 x 10 ⁶ / L	(<100 x 10 ⁶ /L)
	Red cells	31400 x 10 ⁶ / L	(5,000 – 10,000 x 10 ⁶ /L)
<u>DIFFERENTIAL:</u>	(Deposit film)		
	Lymphocytes	95%	
	Monocytes	5%	
<u>GRAM STAIN:</u>	No organisms seen		
<u>GLUCOSE:</u>	5.0 mmol/L		(3.0 - 5.5mmol/L)
<u>TOTAL PROTEIN:</u>	49 g/L		(3.0 - 4.1g/L)

Question 3



Question 5



Question 7

