

## A Subcutaneous Connective Tissue Dystrophy of the Arms and Back, Associated with Symptoms Resembling MYXŒDEMA.

By F. X. Dercum, M. D.

Instructor in Nervous Diseases, University of Pennsylvania  
The University Medical Magazine

Volume 1. October 1888 to September 1889

Thanks to the Library of the College of Physicians of Philadelphia for the copy of the article,  
and to Al Lewis for scanning it for me.

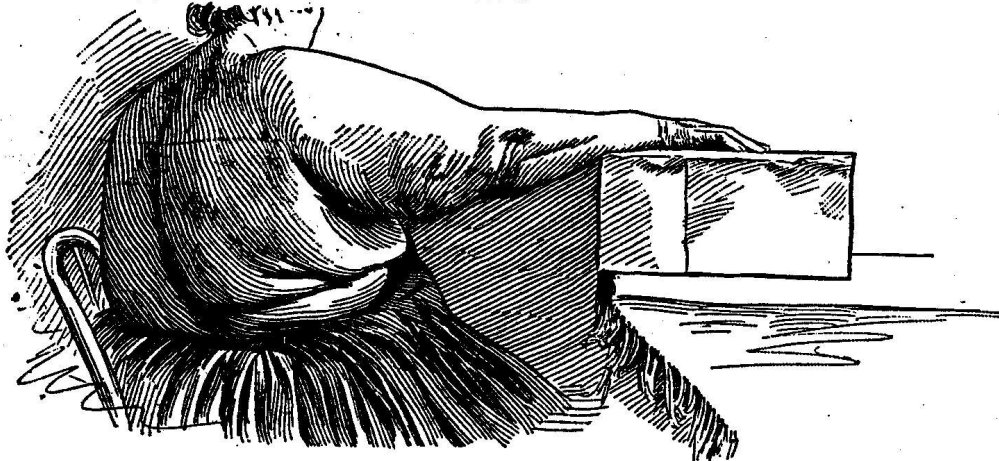
The subject of myxœdema has of late years attracted such widespread attention that observations bearing upon unusual forms or upon allied affections possess special value. The following instance, though evidently not one of myxœdema, at least not typical, is yet closely related to this strange disease. Further, many of its features possess a unique character.

The case is that of a woman aged fifty-one years, a native of Ireland, and by occupation a domestic. She is tall, large-framed, and looks as though she had at one time presented a fine physical development. Her family history did not reveal much of importance. Her father had died at the age of forty-five of erysipelas. Her mother, who had had eighteen children, died at forty of some affection incident to the menopause. Of her brothers and sisters, seven died in early childhood; one, in adult life, of pleurisy; one sister of childbirth; a brother and two sisters of phthisis, while the remaining five are still living and in the enjoyment of average health. She was very positive in her assertion that none of her relatives had ever suffered from symptoms similar to her own. No history of insanity, epilepsy, nor of any neurosis whatever could be elicited.

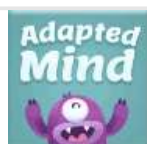Her personal history was as follows: As a child, she had had measles, whooping-cough and scarlet fever, but otherwise, she had been well. When fifteen years of age she menstruated, the function being performed normally from the outset. At eighteen she was married. Some years after, she had an attack of pneumonia, from which she made a good recovery. She had in all seven children besides one miscarriage. Five of her children died in infancy or childhood. She gave the causes of death as cholera infantum in one case, measles in two, congestion of the brain in a fourth, and spasms in a fifth case. At the age of thirty-five her period of sexual activity was abruptly terminated by the appearance of the menopause. From this time up to within two or three years, her health had continued good. She had undergone some increase in weight but beyond this nothing worthy of mention could be recalled. Syphilis and alcoholism were both denied.

About two-and-a-half years ago, she noticed that her arms were becoming very large. The upper arms and shoulders appeared swollen. On some days the swelling seemed more decided than on others. It continued steadily to increase and for about a year was unattended by any other symptom.

FIG. 1.



In November, 1886, she was admitted to the surgical wards of the Philadelphia Hospital for the rupture of a varicose vein of the leg. In the following February she suffered severely from bronchitis for which she was transferred to the medical ward of the same institution. While there she had an attack of severe pain and swelling in the right knee, attended, the record states, by a chill and fever. She was treated for rheumatism and promptly relieved. Two weeks after this she complained of a sharp darting pain in the right arm. It began on the outer aspect above the elbow. It gradually increased in severity and extent, spreading upwards to the shoulder and neck, and downward to the forearm and hand. It was altogether different, she states, from the pain previously experienced in the knee. It was shooting and burning. She felt at times as though hot water were being poured upon the arm and again as though the hand and fingers were being torn apart. No rise of temperature was observed. The pain was often paroxysmal, being very much worse for hours and days at a time, but even during the intervals it was never altogether absent. In fact it continued to grow steadily worse, and on June 4, 1887, she was finally removed to the nervous wards.



Pre-K

1st Grade

3rd Grade

Kindergarten

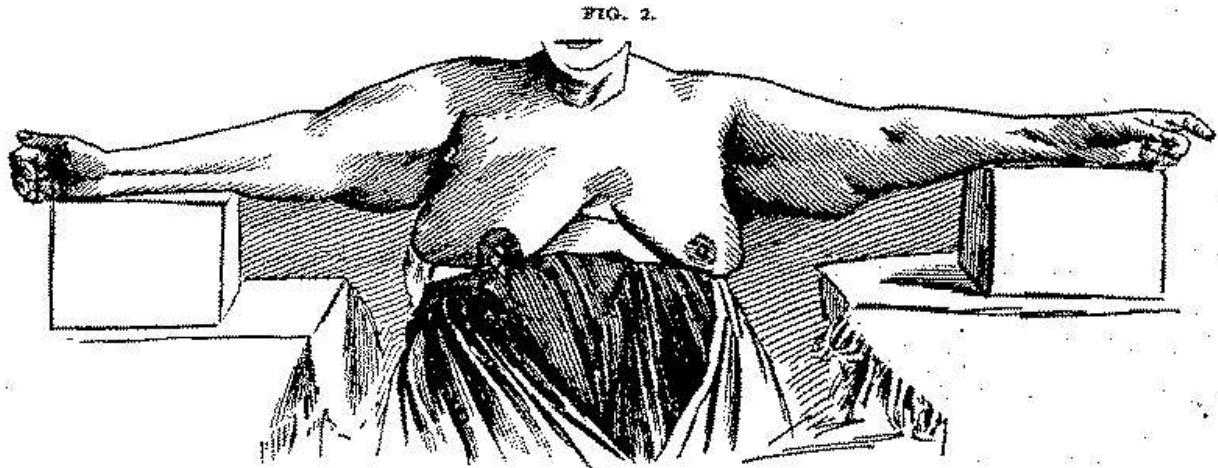
2nd Grade

4th Grade

The sensation to the fingers was very much like that experienced in examining a varicocele, except that the structures appeared more resistant. The skin itself was evidently not thickened. It did not take any part in the swelling, and it was not adherent to the subjacent tissues. It was slightly roughened over the forearms, less so on the arms, shoulders, and hands, while over the fingers it was quite smooth and even glistening. Farther over the forearms and hands it was slightly darkened, small brownish patches and minute epithelial scales being observed; lastly, it was quite dry, perspiration being either absent or diminished.

The right arm was extremely painful on motion, and consequently it was held close to the side and absolutely still. The head at this time was also held in a fixed position for fear that the movement of the neck would give rise to pain in the shoulder. In addition, the arm was also very sensitive to pressure. Pronounced pressure appeared to be absolutely. The nerve trunks were exquisitely sensitive, but this painful condition was not by any means limited to them but permeated the swollen tissues as a whole. A somewhat diffuse region on the outer aspect appeared to be especially affected.

In marked contrast to the right, the left arm could be handled and moved with impunity. No tenderness or pain was present anywhere, though there is a mention in the records of a transient pain in the left wrist, in the latter part of May, 1887.



As regards the muscles, they were evidently as little involved in the swelling as the skin. Nothing comparable to a pseudo-hypertrophy could be made out. On grasping the enlargement over the left biceps and then directing the patient to flex and extend the arm repeatedly, the mass was felt to be unaffected by the movements of the underlying muscle. This was repeatedly confirmed in the case of the forearms and shoulders. That the muscles had in some way suffered was proven by the fact that marked weakness existed in the affected parts. The grip of the right hand was almost nil, while that of the left was greatly diminished. Motion was also retarded, though in the right arm this could easily be explained by the pain. In the left it is possible that the enlarged masses offered a mechanical difficulty.

Examined electrically, both deltoids responded normally to the currents. Neither qualitative nor quantitative change could be detected. The muscles of the arms yielded no satisfactory results owing to the great resistance caused by the swelling. The muscles of the forearms, however, especially of the right, showed a somewhat diminished response to the faradaic current, while the An Cl C appeared to equal the Ca Cl C. In the hands, the thenar and hypothenar groups showed decided lessening in faradaic contractility, while the An Cl C appeared earlier and was decidedly stronger than the Ca Cl C. This reaction was also much more developed in the right side than in the left, though distinctly present in both.

The condition of the surface. sensibility was next studied, and it was found that in the right arm various areas existed in which no response whatever was given to the æsthesiometer. They were large and irregular in shape, and very sharply defined. They were present upon both the inner and outer aspects in the finger tips of the same side, the points could not be at all separated, and sensation was retarded. In the left arm, on the other hand the response was prompt and accurate, with the exception, perhaps, of the outer aspect of the forearm, where some delay and uncertainty existed. In the finger tips, also, sensation was decidedly below normal, the patient not being able to separate the points within one-half to three quarters of an inch. Sensibility to heat and cold was also diminished.

While comparing the responses of the arms with those of other portions of the body, it was discovered that a similar disparity as regards sensation existed between the legs; i.e., the right leg was moderately anæsthetic, while the left showed little or no impairment. This discovery suggested that we had a general and not a purely local affection, to deal with, and accordingly symptoms indicative of a general affection were now sought for.

An examination of the body as a whole, revealed no enlargement nor swelling of any portion save that of the shoulders and arms.

No marked weakness of the legs existed, nor did they reveal any symptoms other than that of impairment of sensation, already described. The face also failed to reveal any swelling whatever, nor could any alteration of sensation be detected. The color of the face was pale, as were also the mucous membranes. There was, however, a little color in the cheeks, more noticeable at times. Her features were well formed and intelligent, though her habitual expression was one indicative of suffering. Her hair was dark and fine and had grown thin over the vertex. Her mind, was, unimpaired, except that at times she was much abstracted. Sometimes she gave conflicting answers to questions, so that the latter had often to be repeated. Especially was this the case when her memory was called into action. Her speech was not slowed, or otherwise altered. At times she was extremely irritable and quarrelsome, and frequently gave much trouble to her nurses.

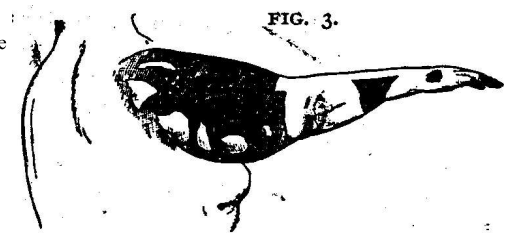


Diagram of the outer aspect of the right arm, the shaded portions represent the areas in which at a recent examination no response was given to the æsthesiometer. In the white patches sensibility was present though not fully up to normal. It should be stated that at the time of making the examination the patient was just recovering from one of her attacks of pain.

Some days after her admission into the nervous ward, June 3, 1887, she had a chill followed by fever and a painful herpetic eruption over the upper portion of the left arm and the upper and anterior portion of the left side of the chest. On the 9th of June, another crop of vesicles made its appearance on the back and on the front of the chest.

Parenthetically it may be mentioned that while in the medical ward, various remedies had been used, and blisters had been applied to the arm, all with little or no effect on the intensity or the character of the pain. Finally sodium salicylate was used gr. xx every three hours. Two days after the record reads: -- "Pain decidedly lessened, except on motion." This improvement continued for two days longer, when the salicylates were stopped and replaced by antifebrin. The pains almost immediately grew worse, and by the 4th of June, the day of her admission to the nervous ward, they were again frightful in their severity. Taking the hint thus offered, the salicylates were again administered, the oil of gaultheria being given in full doses. The character of the pain as well as its intensity appeared to become changed. The pain from being sharp and darting became dull and gnawing and much less severe. The effect of the oil appeared to be very prompt and decided, and that it was really the efficient cause of the diminution of the pain was proven a number of times when nausea and indigestion caused its temporary withdrawal. At these times, the pains invariably grew worse, and on the oil being

As time wore on, the pain though sometimes worse and sometimes better, was in a measure controlled. No noteworthy fact was recorded until October 13<sup>th</sup>, when the patient had another severe attack of bronchitis similar to the one which she had had, while in the medical wards. It was accompanied by much dyspnoea.

A curious fact was observed in the latter part of December. During one of her paroxysms of pain, it was noticed that the swelling of the right arm became more decidedly lobulated. The arm was more sensitive than ever, and on examination hard cake-like masses were felt, resembling, as my resident physician expressed it, the caking of milk in a breast. This caking or increased lobulated feel was subsequently repeatedly noticed during paroxysms of pain. The paroxysms it should be remembered lasted several hours and sometimes several days.

In December, also, she suffered from an attack of pain in the right knee, and in the popliteal space a diffused swelling was felt which exhibited the same curious nodulated, or leech-like feel as did the swelling of the arms. It was also very painful on pressure. It subsided in a few days and no permanent alteration of the tissues could be detected.

In January and February of 1888, the patient again suffered severely from bronchitis. She expectorated at this time large quantities of bloody mucus. In February, also, marked perspiration was noticed over the swollen parts. In March she again suffered from dyspnoea. Her attacks would last for days and be alarming in their intensity. Her right arm was still very painful, the pain now radiating around the trunk to the lumbar region. Bronchitis was again very marked. At this time also a fullness was noticed above the clavicles in the posterior cervical triangles of either side. It was most noticeable on the right side; where it was also sensitive to pressure. During paroxysms of pain it invariably increased in size and density. No swelling was ever observed in the anterior triangles.

In April she experienced another paroxysm of pain of frightful severity. The pain, which involved the right arm and shoulder, right side of trunk and back of neck, now for the first time spread to the face and head. The right side of the neck and the right side of the face became distinctly swollen and presented to the touch the same nodulated feel so characteristic of the swelling in other portions. At the same time the tongue and probably the larynx and pharyngeal tissues became swollen. Her tongue, she said, felt much too large for her mouth and this certainly appeared to be the case. Her speech was much interfered with. Her voice was very hoarse, and she spoke with great difficulty. This condition persisted for upwards of a week when the swelling slowly subsided and all traces of speech interference disappeared. For some time subsequently she spat blood, the source of which I did not determine, though it appeared to come from the throat. Her irritability was extreme and she complained much of bad dreams. The reddish color of the cheeks also became more pronounced, and began spreading until it covered the entire forehead like an intense blush. This blush is now observed to recur with every paroxysm of pain.

During the past summer the patient's condition underwent some change. In some respects it improved. The paroxysms of pain are no longer as frequent and rarely as severe as formerly. Hand in hand with this improvement, sweating became, very abundant. However, during a recent attack of pain, the skin was observed to be quite dry, though as the pain subsided the patient perspired freely. During this attack, as on a former occasion, swelling of the neck and right side of the face occurred. The right supraclavicular swelling again became very prominent. This time, also, a thick, diffuse, welt-like swelling, exquisitely painful, was observed extending from the upper internal angle of the scapula perpendicularly down the back to very nearly the lumbar region. It had the same "caked" feel presented elsewhere. More recently still, the swelling, in the popliteal space returned, and on the inner aspect of the knee a permanent deposit of tissue was found, presenting, in its physical appearances, the same peculiarities as noted in the arms. Pain has now commenced to make its appearance in the left arm, though it is not very marked. The cardiac dyspnoea still occurs every week or two and with great intensity.

Mentally, the patient shows no change unless it be that her memory is becoming more impaired. She is still excessively irritable.

The anaesthetic patches too, noted on the arms and legs have become more pronounced, while new ones have made their appearance. (See diagram.) The last is especially true of the left arm and leg. She also complains of a velvety feel in the tips of the fingers and in the soles of the feet. There is no alteration in the gait. The knee-jerk is lost on both sides. Originally a feeble response could be elicited on the left. General health is not much impaired. Digestion is tolerably good. Respiration, at present, normal. The heart is normal except that there is accentuation of the second sound. Pulse varies from 75 to 96, the average being between 90 and 100. It is somewhat resistant to the feel.

The eyes were kindly examined by Dr. G. E. De Schweinitz. There was contraction of the fields of vision for form and colors of both eyes, most marked in the left. The discs were oval, scleral rings all around and unduly broadened on temporal sides. Disc surfaces, gray-red and deeper layers gray; veins slightly fuller and darker than normal. Choroids a general flannel red. No scotomata.

Hearing was also diminished, though this was not very evident without examination. However, she could not hear the ticking of a watch at a greater distance than one-and-a-half inches.

Examination of smell and taste revealed that these senses were also impaired. The left nostril being plugged, the patient could not with the right nostril distinguish asafetida from cologne. With the left nostril she made the distinction, but not readily, saying only after a time that the bottle containing asafetida smelled of onions. On testing the tongue with solutions of salt and sugar she distinguished one from the other, but with hesitation, saying that both tasted bitter. On comparing the two sides of the tongue, the left responded more readily than the right.

The urine when examined gave the following results: The total quantity for 24 hours was 32 ounces. The specific gravity 1023. The total solids 5 per cent. The quantity of urea for 24 hours, 23.7 grammes. No sugar, no albumin. The quantity of urea cannot be said to be below normal, and the analysis is without special significance.

An examination of the blood from the finger, was kindly made by Dr. F P. Henry, who gave the number of red corpuscles in a c.mm. as 4,940,000; color 70 Percent. White corpuscles not increased.

The enlarged arms were accurately studied in various ways. On December 1<sup>st</sup>, 1887, accurate measurements were made of both arms and shoulders. On July sixth, 1888, these measurements were accurately repeated. (See table.)

Again, in order to determine the possibility of, displacing the swelling by means of pressure, bandages were applied to the left arm as follows: A rubber bandage was evenly applied commencing at the finger tips and extending to and over the shoulder. It was allowed to remain one hour, was then removed, and measurements again taken. Secondly, an ordinary muslin bandage was tightly applied and allowed to remain four hours.

The right arm, it should be remembered, was altogether too painful to permit of this experiment. The accompanying table shows the result. The measurements, it should be stated, were made under as nearly the same conditions as possible.

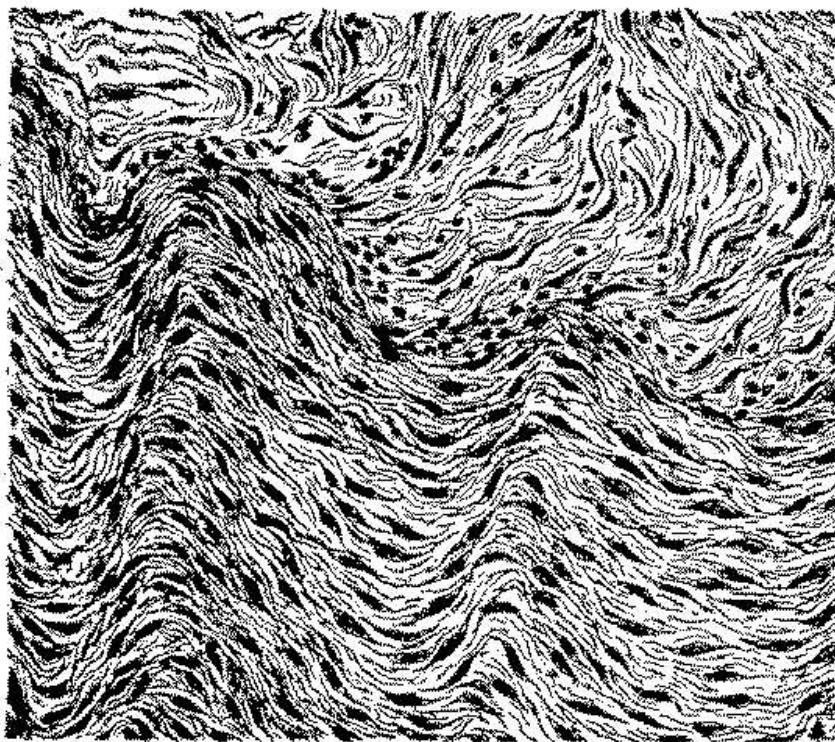
In looking over these columns, it is evident, in the first place, that in the period of seven months intervening between the measurements in December and the measurements in July, very little change had taken place in the size of the swelling in either arm, the differences in the figures, where they exist, are very small. The right arm appears to have lost slightly in its upper and middle Portion and to have gained correspondingly in its lower portion. The forearm remains Practically the same. The left arm appears to have gained somewhat at its greatest circumference but to have remained the same elsewhere. Again it is to be noted that the application of the rubber bandage for an hour was followed, if at all, by a scarcely appreciable reduction in volume. All the measurements remain the same except the circumference at the level of the axilla, which had lost half an inch. A more decided impression appears to have been made by the muslin bandage, which, as stated, was allowed to remain four hours. All of the measurements above the elbow showed a reduction. Over the shoulder three-fourths of an inch were lost, at the level of the axilla one inch, at the greatest circumference half an inch, and midway below also half an inch. These figures, as well as those in the preceding column, are to be compared, it should be remembered, with the measurements of December..

## TABLE OF MEASUREMENTS OF THE ARMS.

	Right arm measured Dec. 1st, 1887.	Right arm measured July 11th, 1888.	Left arm measured Dec. 1st, 1887.	Left arm measured July 11th, 1888.	Left arm rubber band- age applied 1 hour.	Left arm muslin band- age applied 4 hours.
	Inches	Inches	Inches	Inches	Inches	Inches
Circumference of shoulder measured vertically through axilla . . . . .	21	21	21	21	21	20 $\frac{1}{4}$
Around arm at axilla . . . . .	17 $\frac{1}{2}$	17	17 $\frac{1}{2}$	17 $\frac{1}{2}$	17	16 $\frac{1}{2}$
Greatest circumference, middle of arm . . . . .	21	20 $\frac{1}{2}$	19 $\frac{1}{2}$	20 $\frac{1}{2}$	19 $\frac{1}{2}$	19
Circumference midway between greatest circum- ference and elbow . . . . .	19	19 $\frac{1}{2}$	19	19	19	18 $\frac{1}{2}$
Circumference at elbow . . . . .	13	13 $\frac{1}{2}$	12 $\frac{1}{2}$	12 $\frac{1}{2}$	12 $\frac{1}{2}$	12 $\frac{1}{2}$
Greatest circumference of forearm . . . . .	11 $\frac{1}{2}$	11 $\frac{1}{2}$	11	11	11	11 $\frac{1}{2}$
Circumference of wrist . . . . .	7	7 $\frac{1}{4}$	7	7	7	7
Circumference of metacarpus . . . . .	9	9 $\frac{1}{4}$	8 $\frac{1}{4}$	9	9	9

These experiments prove that the swollen tissues cannot be readily compressed, and, would justify the inference that the swelling is not due to any readily dispersible fluid. The fact, however, that a very appreciable reduction took place on applying the resistant and non-elastic muslin bandage is suggestive in view of the following developments

FIG. 4.

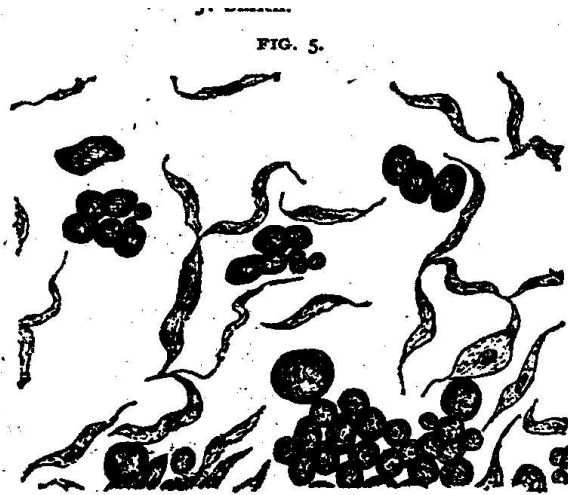


Microscopic drawing from portion excised from right arm, upper third, showing embryonal connective tissue. (Bismarck-brown).—Drawn by Dr. Allen J. Smith.

By means of a Duchenne trocar, fragments for microscopic examination were at various times removed from either arm. In every instance the trocar was plunged well




embryonal connective or mucous tissue. Occasionally fat cells are found in which the fatty metamorphosis has not been complete. Their nuclei, too, can, for the most part, be readily demonstrated. The mucous tissue is distributed between and among them and in no way in considerable proportion.



**Microscopic drawing from portion excised from left arm, middle third, showing fat vesicles, oil drop and embryonal connective-tissue cells, (Osmic acid.)—Drawn by Dr. Allen J. Smith.**

In Figs. 6 and 7 are represented sections of a fragment removed from the middle of the left arm. In this fragment connective tissues, vascular and nervous elements are fortunately present. The change undergone by the connective tissue is very striking. It presents the appearance of thin flattened bands or trabeculae, forming by their confluence and interlacement a beautiful and intricate reticulum having very wide and capacious meshes. The cells composing these trabeculae appear to be broad and flat, though, when presenting by their edges, they seem thin and elongated. Their nuclei are well defined. The thickness of a trabeculae is frequently limited to the thickness of a single layer of cells, so that the reticulum presents an exceedingly delicate appearance. Interspersed with this tissue, transverse sections of groups of fat cells are occasionally seen. The blood vessels found in the fragments present nuclear infiltration, and thickening of their walls. In some instances this is very marked. The most interesting finding, however, in the sections is a more or less complete ganglion<sup>1</sup> of relatively large size, together with a number of non-medullated nerve fibres. The capsule of the ganglion is evidently sclerosed. It is very dense and appears excessively thick. The nerve cells are apparently normal. The non-medullated fibres in turn also reveal decided changes. Their connective tissue appears denser than normal and they present an unusual number of nuclei, which here and there are aggregated in clusters. It should be remarked that when this fragment was removed from the arm, a lymph-like fluid barely tinged with blood made its appearance at the opening of the wound; also that the fragment shrank excessively when placed in alcohol.

**FIG. 6.**

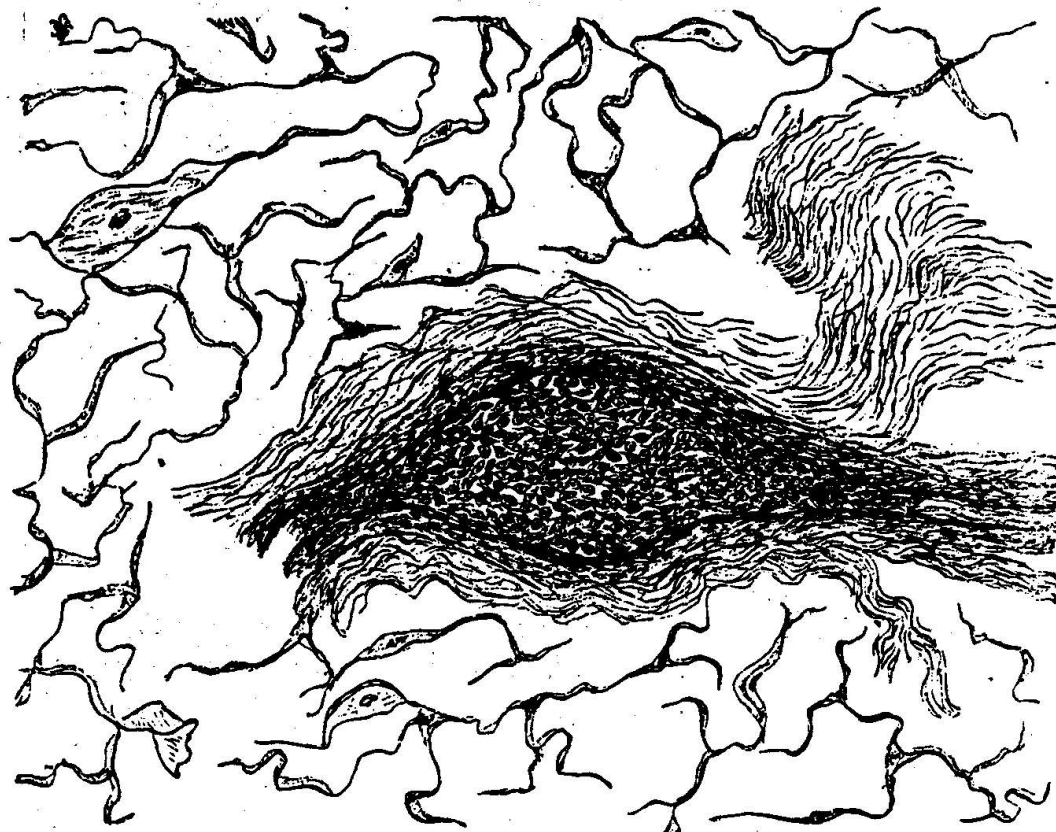


**Microscopic drawing from portion excised from left arm, lower third, showing inflammation of non-medullated nerves. (Carmin.)—Drawn by Dr. Allen J. Smith.**

Inferences based on the examination of minute fragments must be made with caution, and yet the above results, together with the clinical history, fully justify an attempt at the interpretation of this curious case. Let us see what the legitimate inferences are: To begin with, we have a dystrophy accompanied by the swelling of the subcutaneous connective tissue. Secondly, this dystrophy is associated with nervous symptoms pointing to some general affection.

Thirdly, though localized in the arms and back, it is not strictly limited to these regions, having invaded the right leg and the neck, while temporarily the face has also been swollen. Fourthly, the dystrophy has been attended by an increase of connective-tissue elements. Fifthly, this tissue is of a low, undifferentiated or embryonal type. Lastly, we may infer that we have here a marked dilatation of the lymphatics. This is probable for three reasons: First, on account of the nodulated or "bundle-of-cords" feeling; second from the fact that during paroxysms of pain, the swollen mass becomes "caked," and that this "caking" again rapidly subsides; thirdly, from the microscopical appearance of the tissue depicted in Figs. 6 and 7, the meshes of the reticulum being doubtless dilated lymph-spaces.

FIG. 7.



**Microscopic drawing from portion excised from left arm, lower third, showing nerve ganglion with sclerosed capsule. (Carminé.)—Drawn by Dr. Allen J. Smith.**

These inferences are certainly very significant. They seem to indicate that the affection before us is allied to myxœdema. Certainly, the pathological findings, as far as the subcutaneous tissues are concerned, are in harmony with this idea; as are also many of the symptoms. To-be-sure, judging from the literature, the skin is always affected in myxœdema, and if this be considered an essential feature the case before us cannot be placed under that title. However, that we have here a true mucous condition of the subdermal tissue is evident, while dilatation of the lymph spaces and the thickening of the blood-vessels are in perfect harmony with what we know today of the pathology of myxœdema. This is true even of the changes noted in the non-medullated nerve fibres and ganglion. Henrot<sup>2</sup>, for instance, speaks, in addition to other changes, of hypertrophy of the sympathetic system; this hypertrophy involving both the ganglia and their branches. W. Hale White<sup>3</sup> also tells us that while the nerve cells of the ganglia and the nerve fibres are healthy, their connective tissues are increased and sodden. These facts are certainly very suggestive.

As regards the general symptoms, impairment of the tactile sense and of the special senses has been recorded numbers of times in myxœdema. Pain, also, is well recognized as a not infrequent symptom. Its relation to the swelling is however in the present instance very peculiar. No writer has thus far recorded that increase of swelling took place during a paroxysm of pain. Indeed, no writer has mentioned the peculiar lobulated or "bundle-of-cords" feeling which is so evident in this case. We can readily conceive, however, that this condition could be easily overlooked, in fact be beyond observation, if the overlying skin were swollen and thickened.

It should also be stated that in our patient the thyroid gland cannot be felt. This, however, can hardly be regarded as of positive value

The present case differs from myxœdema in a number of points. In the first place, as already stated, there is no involvement of the skin. Secondly, certain prominent nervous symptoms are absent, or at any rate not marked, such as slowing of movement, slowing of thought, and slowing of speech. On the other hand, we should remember that as far as the muscles are concerned, paresis, and diminished or degenerative reaction are present also, as far as thought and speech are concerned, that they are not invariably effected in myxœdema, and further that our patient passed through a distinct though brief period of speech involvement. Again, perspiration is either absent or diminished in myxœdema. It was practically absent in the present case at first, but became profuse later on, the change being accompanied by diminution of pain.

Whatever the exact position of the present case may be, there can be little doubt but that it is related to myxœdema, and, if so, it may materially modify our notions of that disease. Certain it is, that while a relation between myxœdema and diseases of the thyroid has been indisputably established, we are still absolutely in ignorance of the nature or extent of this relationship, or of the intermediate pathological factors if there be any.

I am indebted to Dr. Clara M. Hammond, Dr. S. P. Preston, and Dr. C. W. Sharples, resident physicians of the Philadelphia Hospital, for valuable assistance in the study of the above case.

#### Footnotes.

<sup>1</sup> The presence of this nerve ganglion is perhaps to be explained by supposing the trocar to have grazed a vessel.

<sup>2</sup> Hernot. Des Lésions Anatomiques et de la Nature des Myxœdine. Paris, 1882, also Gaz. De Hôpital No. 23.

<sup>3</sup> W. Hale White. A case of myxœdema with a post-mortem examination, Clinical Transactions, 1885, xviii p. 159-163.

[Return to the List of Articles](#)

Return to the  
[Dercum's Disease Home Page](#)

*Please don't forget that the information provided on this site is designed to support, not replace, the relationship that exists between a patient and his or her physician.*

---

---