

UNDER the name 'residual abscesses' I would include all abscesses formed in or about the residues of former inflammations. Most of them are formed where pus, produced

long previously, has been wholly or in part retained and become dry, or in some form 'obsolete.' But some of them, it is probable, are formed in the thickenings, adhesions, or other lowly organised products of inflammation long past.

Abscesses thus formed are probably well known to many, but, to give them a name and separate illustrations may help to show that they are of more frequent occurrence than is commonly supposed, and are often important in diagnosis.

Suppuration among the products of a former inflammation is probably an illustration of what may be held as generally true concerning many relapsing inflammations, namely that they are due to the disturbed or interrupted nutrition, not only of the tissues deteriorated in previous inflammations, but of the new materials that were formed among them. Thus, in the frequently relapsing inflammations of testicles, and joints, and other parts that one sees in a constantly 'fretful' state, the 'weakness,' 'low vitality,' or 'want of tenacity of composition,' which are indicated by frequent inflammation under every slight provocation, are to be ascribed rather to the remaining products of former inflammations than to the original textures of the parts. Thus adhesions become inflamed, and residues of pus degenerating under any irritation initiate or take part in a renewed suppuration.

Some of the most striking instances of residual abscesses may be found in connection with diseases of the spine.

A woman about 40 years old had, as was supposed, acute pleurisy; but it may be believed that, whether with or without pleurisy, she had acute caries of the spine, for when she had recovered from the pain and other severe signs of her malady, a very prominent angular curvature of the lower dorsal part of her spine was found. She remained in feeble health with various evidences of scrofula, but no new disturbances appeared at or near her spine till about six years after the formation of the angular curvature, when a large lumbar abscess formed. Its formation was attended with very little disturbance of the general health, and it remains nearly stationary.

I suppose that in this case the abscess formed in or about the residue of inflammatory products which had been at rest for six years. The supposition is justified by a similar but plainer case.

A lady about 30 years old had well-marked angular projection of the last two lumbar vertebræ and a psoas abscess, which

extended far down the outer part of the thigh, and might be estimated to contain at least two pints of pus. She had not suffered severely during the progress of the disease, but was very weak and wasting. I advised her to remain in perfect and constant rest on a couch, and to be carefully nourished, and kept as nearly as possible in good general health. At the end of two years, during which this plan was carefully carried-out, the abscess, having slowly diminished, had disappeared. Nothing could be felt but what might be considered shrunken and hardened abscess-wall, and the patient was fat and strong. She resumed active habits of life, and among other feats of good health walked to the summit of the Rigi and some other Swiss mountains. Thus she continued well and vigorous for four years; then she had a severe and tedious bronchitis, and became very weak, and an abscess as large as the previous one quickly formed. Again she rested for two years, but with no other advantage than that of regaining the strength lost during the bronchitis. The abscess slowly increased, but with very little constitutional disturbance; and at the end of two years and a half from its appearance, it opened spontaneously and discharged.

It now appears in process of healing.

The state of parts in the intervals of suspense in these cases, as well as much of the general history of residual abscesses, may be illustrated by a specimen in the Museum, represented in the adjoining plate (I.). It shows two psoas muscles with cavities occupying the place of their whole interior substance. The cavities, walled-in by the thin remains of muscular substance, and lined by thin membranes, were filled with the half-dry remains of pus. Externally the muscles appeared healthy, except in being pale; they were of natural size, and the adjacent structures were all healthy, unless for a very slight superficial roughness of the body of one lumbar vertebra.

The history of this case is not known. The specimens were taken from a body sent to the dissecting rooms; yet it is plain enough that two psoas abscesses were formed, that they failed of being discharged, and that the retained pus withered and became half dry and obsolete; and it is equally plain that parts left thus unsound must have been very susceptible of fresh inflammation, and if inflamed would have become the seats of residual abscesses.

Collections of withered and half-dried pus, similar to these, may be found not rarely near joints long ago diseased but now quiet. They are sometimes seen during excision of the knee,

especially in cases in which the operation is done, not for any great severity of disease, but for repeated disabling relapses of inflammation in a joint without evident suppuration. Similarly, an abscess, long quiet, but with pus little changed, was found in the following case:—

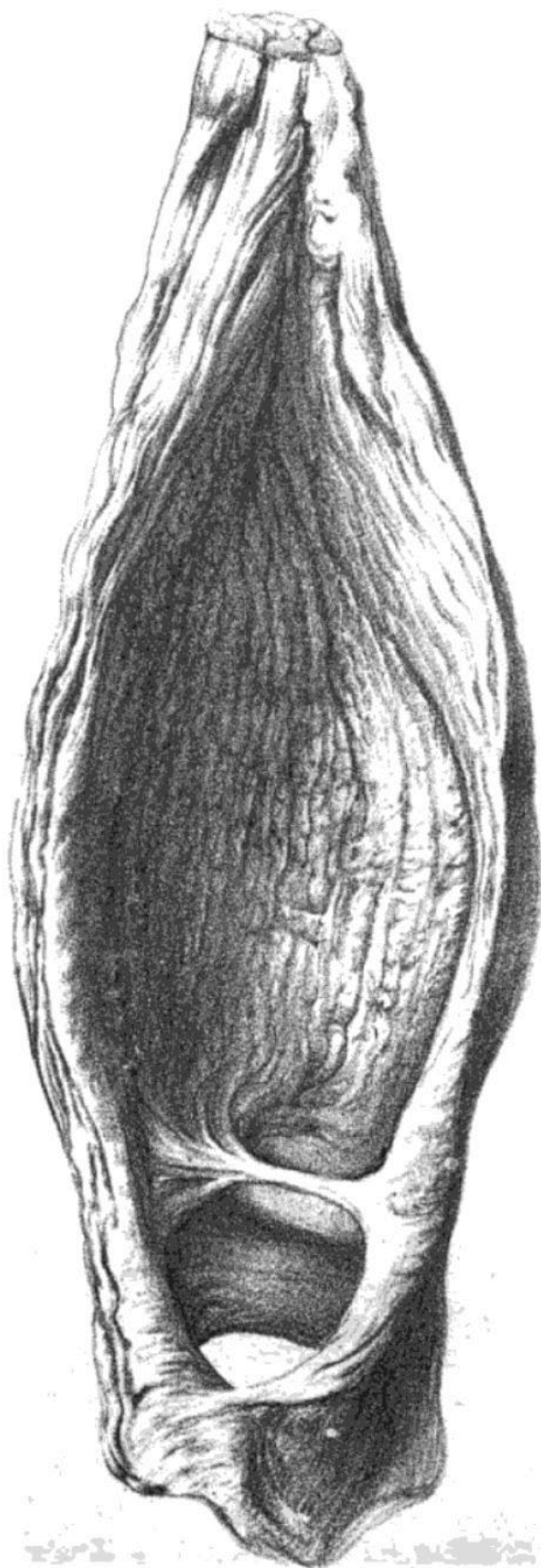
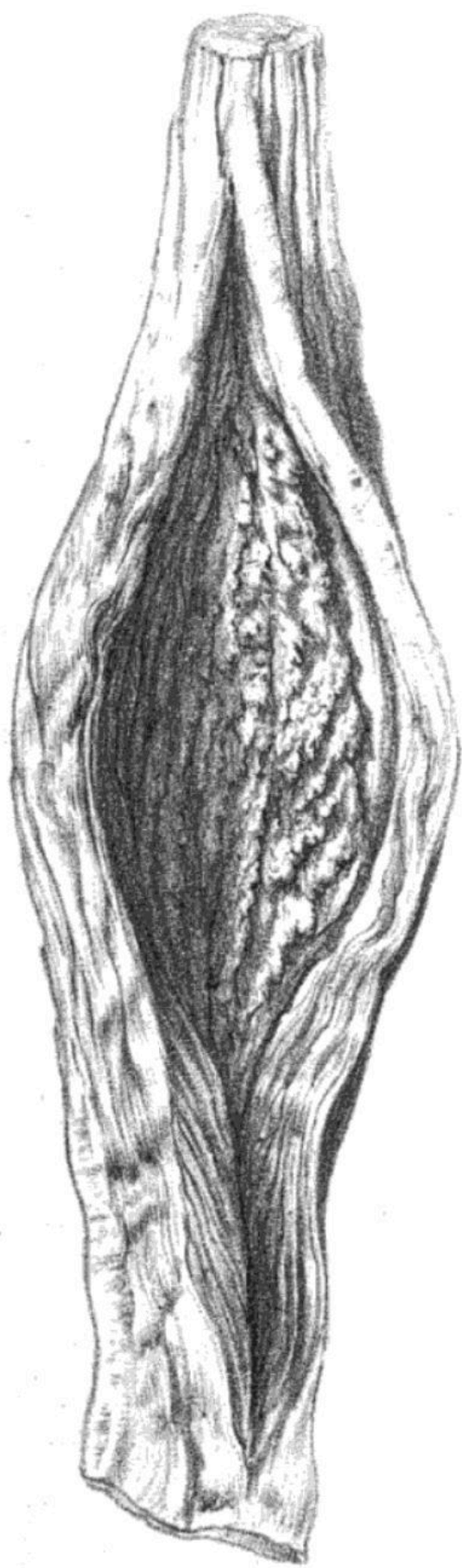A woman nearly 30 years old, in good general health, was admitted under a late colleague with a circumscribed swelling over and above the left sacro-iliac symphysis, painless and elastic. It was thought to be a fatty tumour, but the operation begun for its removal let out pus from a cavity leading, by a narrow track, to the hip-joint. Disease of this joint had existed twenty years previously, and had subsided, without apparent suppuration, after a year's rest. The patient had remained lame with stiffness of the joint, but with no other distress, and the abscess had not been observed for more than two years before its opening.

Cases of residual abscess such as these are, not rarely, the cause of disappointment in cases of diseased joint, especially of diseased hip-joints apparently repaired without suppuration, and remaining, to all appearance, well for one or more years.

A woman 25 years old, healthy and strong, came with abscess over the left hip-joint. When 11 years old she had disease of this hip, followed by nearly two inches shortening of the limb. At 18, after a very long interval of apparent recovery, a swelling formed under the sheath of the femoral vessels, and now at 25 it contained half a pint of fluid, which one could not doubt was pus. The swelling was painless, and was slowly increasing without any disturbance of the general health. It was left for spontaneous discharge.

A student, 20 years old, related that he had often, in early life, had scrofulous disease of the cervical glands, and when he was 13 had inflammation of the left hip-joint, which, without apparent suppuration, was followed by shortening of the limb to the extent of about three inches. Of these three inches about half was due to defective growth of the limb, the remainder to ulceration or absorption of the head and neck of the femur. But the new-formed joint, if such there was, was freely movable and so sound that, for the last five years, he had been constantly gaining strength in the limb and living actively without pain or illness.

During the last ten months he had observed a gradually increasing swelling in the upper and outer part of the thigh, but it gave no pain or trouble till, within the few days before my first seeing him, the skin over it inflamed. The swelling



felt now like a chronic abscess pointing, and after a few days' treatment was punctured. About ten ounces of thick pus were let out. No fever or other serious disturbance followed, and the abscess-walls gradually contracted, leaving a sinus four or five inches long leading towards the remains of the acetabulum. To heal this, tincture of iodine was injected. Three days afterwards rigors and a sharp attack of fever ensued, and these were followed by swelling and pain about the sinus, and then by a copious discharge of 'chalky' matter and thick pus.

A large quantity of this chalky matter, which could only be regarded as a residue of pus formed five or more years previously, in the earlier stages of the disease of the joint, was discharged with fresh-formed pus and small fragments of cancellous bone. After many months the discharge diminished, and only a long sinus remained; but signs appeared of tuberculous disease of the genital and urinary organs, and with this the patient died—about nine years from the first indication of disease of the hip-joint, and about three years from the first appearance of the residual abscess.

Another group of cases which I believe may be referred to residual abscesses are found among instances of necrosis of the interior of long bones. Two remarkable examples have lately been in the Hospital.

In February last a woman, 38 years old, was in Sitwell Ward under my care, with what I believed to be abscess in the head of the tibia. There was general swelling at the part, and heat, and at times such pain as the patient called 'frightful' and 'agony.'

When she was ten years old—that is, twenty-eight years before admission—she had inflammation of the leg in consequence of a fall, and this was followed by exfoliation of several small portions of the upper part of the tibia. They were discharged through abscesses or sinuses which remained open for five years, and in or about which many attacks of inflammation occurred. At the end of these five years the patient appeared well: and so she remained for twenty years, leading an active life and feeling no pain or distress in the limb. Three years before her admission, in consequence, probably, of over-fatigue, the leg began to be painful and slightly swollen about the upper part of the tibia; and from this time onwards she suffered, especially in winter, from the fierce attacks of pain for which she came to me.

Shortly after her admission, I perforated the head of the

tibia at the place of most intense tenderness, close by some of the scars of the openings from which sequestra had been discharged. The drill entered a small abscess-cavity and a few drops of pus escaped. The operation was followed by complete release from pain.

In the next bed to this patient was a girl 13 years old, who had had similar necrosis in the upper part of the tibia following injury five years previously. At various times sequestra had been discharged or removed: then followed an interval of apparent health, and then abscess, such as might be called residual, in the cavity that had contained sequestra. This abscess was perforated and slowly healed.

In 1860 I saw, with Mr. Edgar Barker, a lad 14 years old, who, fifteen months previously, had acute periostitis and necrosis of both tibiæ at and about the junctions of their middle and lower thirds. I removed portions of the inner layers of the walls of both the tibiæ: the sequestra being almost as symmetrical as the disease had been: both lying in similar cavities in the walls and with similar cloacæ. The wounds healed favourably and all appeared well for nearly seven years.

At the end of this time, the patient's general health having been much reduced during residence in China, abscess slowly formed at the lower part of the right tibia, and I had to perforate it. The abscess cavity was evidently in or very near that from which the sequestra were removed seven years before. The wounds of the operation healed, but the tibia is still frequently inflamed.

In none of these cases did I find distinct residues of pus in the cavities from which sequestra had been removed and in which, long afterwards, suppuration ensued. Yet it is highly probable that, with stricter search than is possible during an operation, such residues would be found: for the condition of sequestrum-cavities, with rigid walls and suppurating linings, is just that in which we might expect an incomplete filling up with new tissue, and remaining spaces filled with residues of pus.

Many other cases might be cited of residual abscesses with histories and characters closely resembling those just related. Thus, in lymphatic glands, left large and indurated after scrofulous inflammation in early life, it is not rare to see, many years later, fresh inflammation followed by abscess and discharge of thick caseous and calcareous matter, the residues of the earlier inflammatory formations. And by the rectum,

hardnesses, remnants of inflammation threatening or producing abscess, are nearly sure to suppurate, though many years of apparent quietude may elapse. And I know a case in which, as I believe, abscess formed near the cæcum or ascending colon, and was not discharged, till twenty years later suppuration ensued, and pus was discharged at the loin and into the colon.

Taken together, these cases may suffice to illustrate the formation of abscesses in the seats of inflammations long past, especially where residues of pus remain. Such residual abscesses may form, as in the seats of past necrosis, with all the pain and constitutional disturbance commonly attendant on acute abscesses; but much more frequently they form slowly and without pain or fever or any other distress. In these cases they acquire great interest from the difficulty of diagnosis. They may resemble bursæ or fatty or fibro-cellular tumours, and only a carefully ascertained history of the case may suffice for their discrimination. On the ground of history, a residual abscess may be suspected whenever a swelling, not altogether unlike an abscess, appears in or near a part that has long previously been the seat of an inflammation, especially if it appears or greatly increases soon after anything that has impaired the general health.

In the treatment of residual abscesses, no other rules need be observed than those generally accepted for the treatment of ordinary acute and chronic abscesses. I have only once seen a residual abscess disappear without discharge: and the probability of such an event is so slight that I would rather promote than retard their suppuration. But as to the time and manner of opening such abscesses, and the after-treatment, the general rules for the management of ordinary abscesses may suffice.

Many of the cases I have related are instances of the very long time during which a part once damaged by inflammation may remain unsound: and the disappointment felt on the occurrence of a residual abscess may, to some, seem to cast discredit on the practice of permitting or aiding the absorption or drying-up of chronic abscesses connected with disease of spine or joint. But the discredit is not just: for many patients in whom such abscesses have disappeared have never suffered after-consequences: and, so far as I have yet seen, the healing of discharged residual abscesses is quicker, and attended with much less disturbance, than the healing of first abscesses of the same size and in similar situations.